



## Clinical case

### Double volvulus of the sigmoid and transverse colon in a resource-limited setting

Double volvulus du côlon sigmoïde et transverse dans un contexte de ressources limitées

S Younous\*<sup>1,2</sup>, M Kalli<sup>3</sup>, A Oumar<sup>2</sup>, S Ismael<sup>3</sup>, C Lamadine<sup>1</sup>, N Ahmat<sup>1</sup>, A Rahma<sup>1</sup>, S Ahmat<sup>1</sup>, C Ouchemi<sup>3</sup>

#### Résumé

Objectifs : L'occlusion intestinale aiguë mécanique en Afrique subsaharienne est le plus souvent causée par une obstruction colique tumorale, une strangulation adhésive ou un volvulus isolé. Le double volvulus associant le côlon pelvien (sigmoïde) et le côlon transverse est exceptionnel. Cette étude vise à évaluer la prise en charge du double volvulus colique dans notre contexte.

Cas clinique : Un patient de 65 ans a été admis au service de chirurgie générale du Centre Hospitalier Universitaire d'Abéché, dans l'est du Tchad, pour des signes cliniques d'occlusion intestinale aiguë. La radiographie abdominale standard a mis en évidence une image caractéristique de double anse. Une laparotomie médiane exploratrice a révélé un volvulus simultané du côlon pelvien et du côlon transverse, sans signe de nécrose intestinale. Une hémicolectomie gauche a été réalisée. Les suites postopératoires ont été simples et le patient est sorti au 14<sup>ème</sup> jour postopératoire.

Conclusion : Le double volvulus colique est une urgence chirurgicale rare, dont le diagnostic est le

plus souvent peropératoire. Une prise en charge chirurgicale rapide et adaptée est essentielle pour assurer une évolution favorable et préserver le pronostic vital du patient.

Mots-clés : Double volvulus, côlon sigmoïde, côlon transverse, hémicolectomie, Centre Hospitalier Universitaire d'Abéché.

#### Abstract

Objectives: Acute mechanical intestinal obstruction in sub-Saharan Africa is most commonly caused by tumoral colonic obstruction, adhesive strangulation, or isolated volvulus. Double volvulus involving both the pelvic (sigmoid) and transverse colon is extremely rare. This study aims to evaluate the management of double colonic volvulus in our setting.

Clinical case: A 65-year-old male patient was admitted to the general surgery unit of the Abéché University Hospital Center in eastern Chad with clinical signs of acute intestinal obstruction. Plain abdominal radiography showed a characteristic double-loop image. Exploratory midline laparotomy revealed a simultaneous volvulus of the pelvic and transverse

colon, without evidence of bowel necrosis. A left hemicolectomy was performed. The postoperative course was uncomplicated, and the patient was discharged on postoperative day 14.

**Conclusion:** Double colonic volvulus is a rare surgical emergency with diagnosis most often established intraoperatively. Prompt and appropriate surgical management is essential to ensure favorable outcomes and to preserve the patient's vital prognosis.

**Keywords:** Double volvulus, sigmoid colon, transverse colon, hemicolectomy, Abéché University Hospital Center.

---

## Introduction

Sigmoid colon volvulus is a medico-surgical emergency characterized by strangulation of the sigmoid loop around its mesocolic axis, resulting in a distal mechanical intestinal obstruction [1]. When this phenomenon occurs simultaneously at two different levels of the colonic segment, it is referred to as double volvulus [2]. According to Lianos, the most common sites of colonic volvulus are the sigmoid colon (75%), the cecum (22%), the transverse colon (2%), and the left colic flexure (1–2%) [3]. Double volvulus involving both the pelvic colon and the transverse colon in a single patient is a rare entity and is often discovered incidentally in daily surgical practice in peripheral and resource-limited settings. For this reason, we decided to report this case and to discuss, through a review of the literature, the etiopathogenic aspects, diagnostic approaches, and therapeutic management.

## Clinical case

This was a 65-year-old male patient referred from a nearby district hospital for management of an acute intestinal obstruction evolving for seven days. On history taking, there was a notion of traditional treatment using herbal decoctions, self-medication, and cessation of bowel movements. The patient also

had a history of chronic constipation. On general examination, body temperature was 38.5°C, blood pressure was 150/100 mmHg, heart rate was 61 beats per minute, with mild skin folds suggestive of dehydration and a deterioration of the general condition classified as WHO stage III. The abdomen was asymmetric and immobile, with the presence of peri-umbilical scarifications (Figure 1). Abdominal palpation revealed mild tenderness. Percussion showed pre-hepatic dullness and diffuse tympanism. On auscultation, bowel sounds were absent. In view of these findings, a diagnosis of acute distal intestinal obstruction was suspected.

Laboratory investigations revealed a white blood cell count of 8,700/mm<sup>3</sup>, hemoglobin level of 10.2 g/dL, and platelet count of 325,000/mm<sup>3</sup>. Blood glucose was 1.07 g/L. Plain abdominal radiography showed two inverted “U-shaped” air–fluid levels, also described as a double-loop image, consistent with double colonic obstruction due to volvulus (Figure 2). The diagnosis of colonic obstruction caused by volvulus was established. Initial resuscitation with crystalloids and blood transfusion was initiated, and the patient was taken to the operating room.

Under general anesthesia, surgical exploration through a midline laparotomy revealed a double volvulus of the sigmoid colon and the transverse colon, each twisted by one turn (Figure 3). The intestinal loops were dilated, ecchymotic, and gangrenous-looking but without frank necrosis. A wide left hemicolectomy removing both volvulized segments was performed, followed by a left iliac colostomy using the Hartmann procedure (Figure 4). The immediate postoperative course was uneventful, allowing the patient to be discharged home on postoperative day 14.

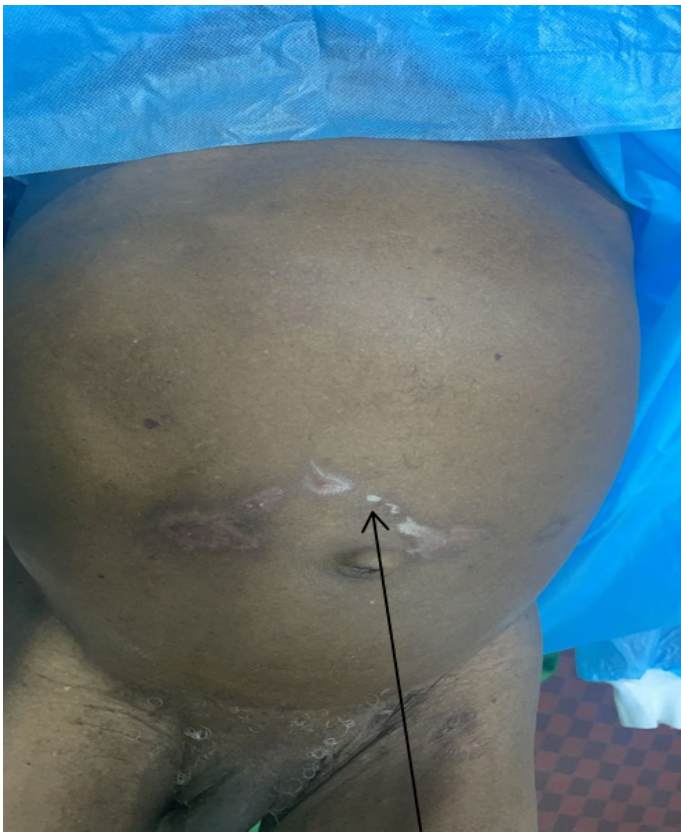

Figure 1: Abdominal asymmetry with peri-umbilical scarring

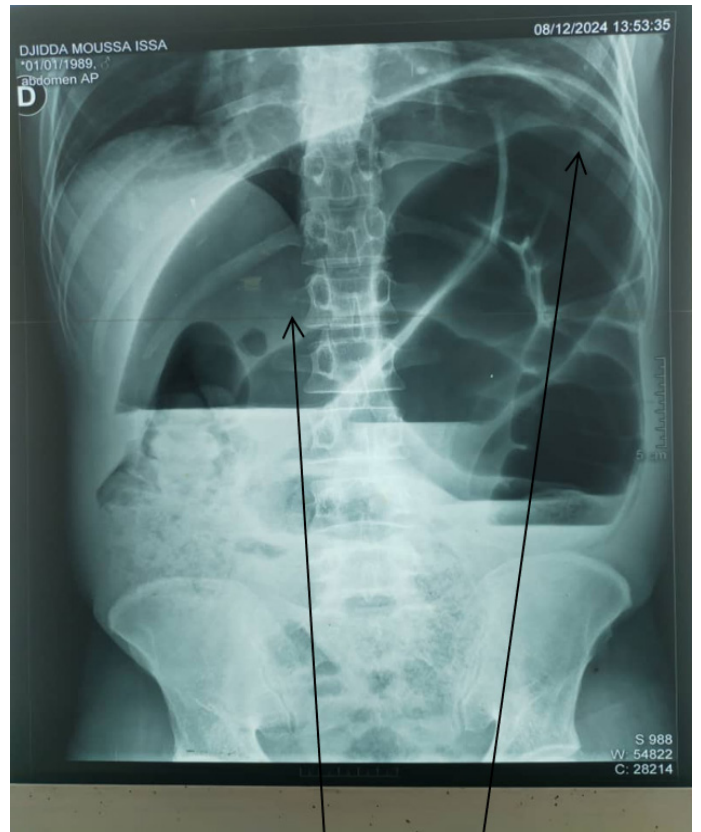


Figure 2 : X-ray suggesting a double volvulus of the sigmoid colon and the transverse colon

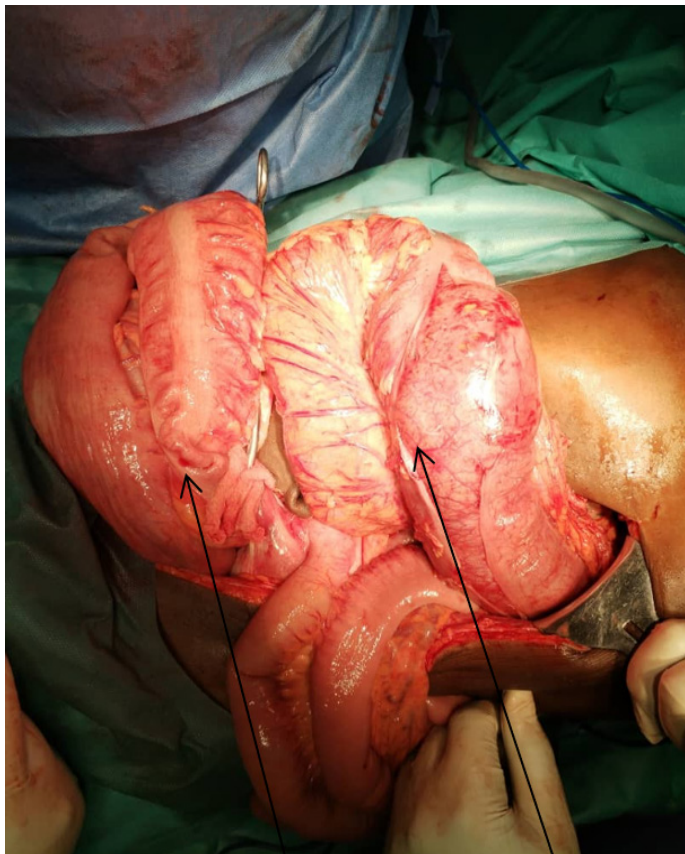

Figure 3: Intraoperative image of a double volvulus

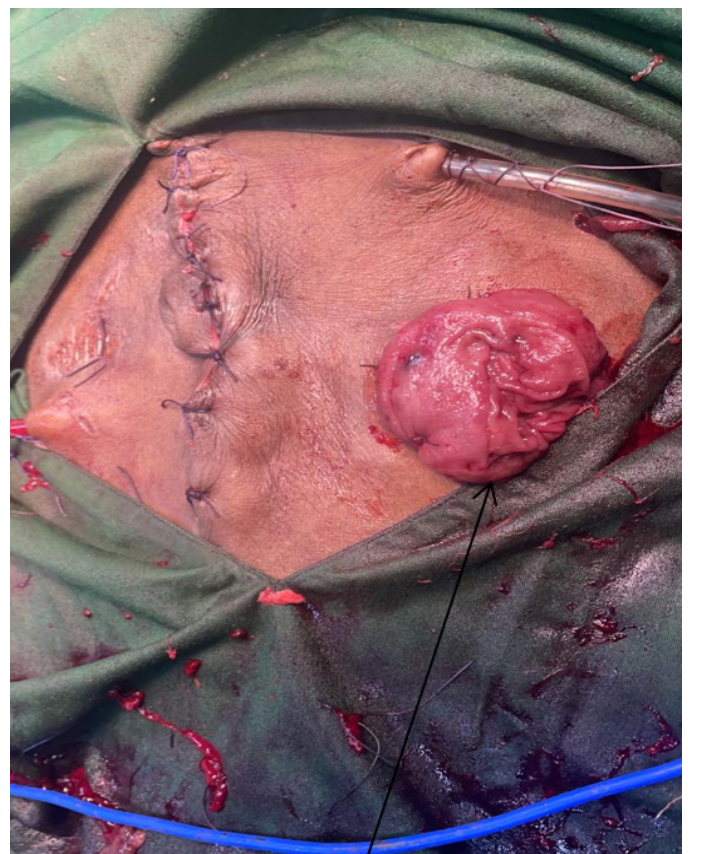

Figure 4: Intraoperative image of a double of the sigmoid colon and the transverse colon

## Discussion

Sigmoid colon volvulus accounts for 9.2% of intestinal obstructions in Chad, compared to 69% in Ethiopia, 35.5% in Burkina Faso, and 35.2% in Mali [2,4–6]. This high prevalence of sigmoid volvulus in sub-Saharan Africa may be partly explained by racial factors, particularly the dolichomorphic tendency of the African colon, characterized by a narrower base of the sigmoid mesocolon, which predisposes to torsion. This is often associated with dietary factors such as high-fiber intake, which promotes chronic constipation [6].

Delayed consultation significantly impacts the patient's general condition, as in our context of geographic isolation, patients often seek care first from traditional healers or local marabouts before attending healthcare facilities. This was the case for our patient, who presented seven days after symptom onset. Similar observations have been reported by other authors [7,8].

The clinical presentation of this patient admitted as an emergency was dominated by obstructive syndrome, a finding consistent with reports from other authors who observed overt obstruction at admission [2,3]. In this case, plain abdominal radiography revealed two inverted “U-shaped” air–fluid levels, indicative of colonic obstruction due to volvulus. Given our limited resources, clinical examination and basic imaging were sufficient to suspect the diagnosis of colonic volvulus. Although computed tomography, which was unavailable in our setting, remains the gold standard for assessing bowel wall viability, identifying the site of obstruction, and determining the etiology [9], in remote areas such as ours, access to CT scanners, image transmission, and telemedicine could significantly improve diagnostic accuracy [10]. Nevertheless, patient history (seven days of evolution, chronic constipation, cessation of bowel movements), clinical findings (abdominal asymmetry), and the double-loop image on plain radiography were sufficient to confirm the diagnosis and indicate surgical intervention. Therapeutically, general anesthesia was

used. Intraoperatively, supra- and infra-umbilical midline laparotomy revealed a double volvulus of the pelvic and transverse colon with dilated, ecchymotic, and compromised but viable bowel loops. A left hemicolectomy with left iliac colostomy using the Hartmann procedure was performed, considering the delayed presentation, advanced age, poor general condition, absence of bowel preparation, and anemia. Similar approaches have been reported by other African authors [7,8,11].

In all cases, therapeutic management depends on the patient's clinical status, the delay before treatment, intraoperative findings, available technical resources, and the surgeon's experience [4]. Postoperative outcomes were favorable after correction of anemia and dehydration, allowing discharge on postoperative day 12.

## Conclusion

Double volvulus involving the pelvic and transverse colon in a single patient is a rare condition. The clinical presentation is that of intestinal obstruction, and the diagnosis is usually established intraoperatively. In the absence of bowel necrosis and in an unstable patient, left hemicolectomy with Hartmann-type colostomy was the therapeutic option of choice in this case, in accordance with the literature for late presentations. Prognosis depends on patient age, consultation delay, intraoperative local conditions, and the surgeon's experience. Health education aimed at behavioral change may help reduce consultation delays, which remain a major prognostic factor in our setting.

---

## \*Correspondence

Seïd Younous

[seidyounous3@gmail.com](mailto:seidyounous3@gmail.com)

**Available online** : January 22, 2026

1 : Surgery Department, Abéché University Hospital  
2 : Faculty of Health Sciences of Abéché, Chad  
3 : Faculty of Human Health Sciences of N'Djamena,  
Chad

© Journal of African Clinical Cases and Reviews 2026

**Conflict of interest :** None

## References

- [1] Borie F, Bertrand M, Souche F. Occlusions intestinales aiguës de l'adulte : diagnostic. *EMC Gastroenterol.* 2019;14(1):1-22.
- [2] Keita K, Diarra A, Keita S, Keita F, Coulibaly O, Traoré A, et al. Double volvulus of the transverse colon and sigmoid at Kati University Hospital (BSS): about two cases. *Surg Sci.* 2021;12:296-301.
- [3] Lianos G, Ignatiadou E, Lianou E, Anastasiadi Z, Fatouros M. Simultaneous volvulus of the transverse and sigmoid colon: a case report. *G Chir.* 2012;33(10):324-326.
- [4] Choua O, Mignagnal K, Moussa A, Okim A, Kalli M, Kalki N. Résultats du traitement du volvulus du sigmoïde à N'Djaména (Tchad). *Eur Sci J.* 2015;11(21):185-188.
- [5] Soressa U, Mamo A, Hiko D, Fentahun N. Prevalence, causes and management outcome of intestinal obstruction in Adama Hospital, Ethiopia. *BMC Surg.* 2016;16(1):38.
- [6] Kambiré J, Ouédraogo S, Ouédraogo S, Bere B, Zida M. Résultats de la prise en charge des urgences chirurgicales coliques au centre hospitalier universitaire régional de Ouahigouya, Burkina Faso. *Eur Sci J.* 2020;16(15):173-182.
- [7] Samlali A, Boussaidane S, Hamri A, Nardjis Y, Benelkhalat R. Synchronous volvulus of the transverse and sigmoid colon: a rare cause of large bowel obstruction. *Pan Afr Med J.* 2021;38:231.
- [8] Ndong A, Diao M, Tendeng J, Diallo A, Manyacka N, Konaté I. Synchronous sigmoid and transverse volvulus: a case report and qualitative systematic

review. *Int J Surg Case Rep.* 2020;75:297-301.

- [9] Nicholas T, Manasewitsch B, Michael T, Lee B, Anthony N, Khuu M, et al. Synchronous volvulus of the transverse colon and caecum associated with scleroderma and lupus. *Radiol Case Rep.* 2021;16(2):273-277.
- [10] Kras E. Médecine d'urgence dans les pays à ressources limitées. 2e éd. Marseille: Santé Sud; 2024.
- [11] Kambiré J, Ouédraogo S, Ouédraogo S, Zida M. Volvulus synchrone du sigmoïde et du transverse. *JACCR Africa.* 2021;5(1):186-189.

## To cite this article :

S Younous, M Kalli, A Oumar, S Ismael, C Lamadine, N Ahmat et al. Double volvulus of the sigmoid and transverse colon in a resource-limited setting. *Jaccr Africa* 2026; 10(1): 8-12

<https://doi.org/10.70065/26101.jaccrAfri.002L012201>